

Acute and Subacute Toxicity Assessment of Crude Aqueous Extract of *Melastoma malabathricum* Leaves

Ying Ju Tan^{1,2}, Syahida Maarof³, Fhaisol Mat Amin², Soo Peng Koh³,
Khozirah Shaari^{1,4}, Rozaihan Mansor⁵, Mohd Firdaus Othman²,
Mohd Shaharizan Mohd Sham², Ainu Husna MS Suhaimi² and Geok Hun Tan^{6*}

¹Institute of Bioscience, Universiti Putra Malaysia, 43400 Serdang, Selangor, Malaysia

²Livestock Science Research Centre, Headquarters MARDI, Persiaran MARDI-UPM, 43400 Serdang, Selangor, Malaysia

³Food Science and Technology Research Centre, Headquarters MARDI, Persiaran MARDI-UPM, 43400 Serdang, Selangor, Malaysia

⁴Department of Chemistry, Faculty of Science, Universiti Putra Malaysia, 43400 Serdang, Selangor, Malaysia

⁵Department of Farm and Exotic Animal Medicine and Surgery, Faculty of Veterinary Medicine, Universiti Putra Malaysia, 43400 Serdang, Selangor, Malaysia

⁶Department of Land Management, Faculty of Agriculture, Universiti Putra Malaysia, 43400 Serdang, Selangor, Malaysia

ABSTRACT

Melastoma malabathricum (MM), also known as “Senduduk,” is a medicinal herb commonly used among the indigenous folks in Malaysia as traditional medicine for practical purposes. Many toxicity profile studies have been carried out on MM extract. However, very few studies have described the toxicity profile of MM aqueous extract. Therefore, this study aimed to investigate

the acute and subacute oral toxicity of MM crude aqueous extract using Sprague Dawley rats. A total of 34 female Sprague Dawley rats were randomly divided into six groups for acute (n=5) and subacute (n=6) studies. The duration for the acute and subacute studies was 14 days and 28 days. A single dose of MM extract was fixed at 3000 mg/kg and did not show any signs of toxicity or mortality during 14 days of observation. In the 28 days repeated dose toxicity test, the rats were orally fed with three different doses, 100 mg/kg, 500 mg/kg, and 1000 mg/kg of body weight/day, revealed no major significant change ($p<0.05$) in their physical appearance, behaviour, haematology,

ARTICLE INFO

Article history:

Received: 19 November 2024

Accepted: 02 December 2024

Published: 30 May 2025

DOI: <https://doi.org/10.47836/pjtas.48.4.02>

E-mail addresses:

yjtan@mardi.gov.my (Ying Ju Tan)

syahida@mardi.gov.my (Syahida Maarof)

fhaisol@mardi.gov.my (Mat Amin Fhaisol)

karenkoh@mardi.gov.my (Soo Peng Koh)

khazirah@upm.edu.my (Khozirah Shaari)

rozaihan@upm.edu.my (Rozaihan Mansor)

mfier@mardi.gov.my (Mohd Firdaus Othman)

msms@mardi.gov.my (Mohd Shaharizan Mohd Sham)

shusna@mardi.gov.my (Ainu Husna MS Suhaimi)

geok_hun@upm.edu.my (Geok Hun Tan)

*Corresponding author

serum biochemistry indicators, and relative organ weight when compared to the control group. The findings were supported by a microscopic histopathology examination of the liver after feeding with MM crude aqueous extract. This study suggests that oral application of 3000 mg/kg in acute toxicity assay and 100 mg/kg, 500 mg/kg, and 1000 mg/kg of MM crude aqueous extract in subacute toxicity assay do not induce adverse effects in rats.

Keywords: Acute toxicity, aqueous crude extract, *Melastoma malabathricum*, Senduduk, subacute toxicity

INTRODUCTION

Melastoma malabathricum (MM) is a popular herb among the indigenous folks in Malaysia for its antimicrobial (Choudhury et al., 2011), anti-inflammation (Mazura et al., 2007) and antioxidant properties (Kumar et al., 2013). It has been traditionally applied for medical practical purposes. However, assessing the plant's toxicity is crucial to ensure its safety before use in medicinal applications. Toxicity refers to poisonous compounds within the plant that can harm cells. Exposure to hazardous chemicals or constituents can result in negative health consequences for individuals. It is worth noting that plants utilised in alternative medicine might contain toxic substances. Thoroughly assessing these effects is essential to safeguarding public health.

In 2012, Alnajjar et al. (2012) performed the first acute toxicity assessment on ethanol-extracted MM plant samples in 2000 and 5000 mg/kg concentrations. In the following years, experiments were conducted to explore the toxicity of MM ethanol and methanol extracts using concentrations of 500 and 1000 mg/kg (Kamsani et al., 2019; Zahi et al., 2017). On the other hand, Reduan et al. (2020) assessed the dermal acute toxicity of MM ethanolic extracts in tests. All these investigations collectively indicated that MM extracts did not induce immediate adverse reactions either systematically or on the skin.

Many studies have documented diverse outcomes, potentially resulting from multiple factors that incorporate variations in experimental protocols, methodologies, herbal extraction techniques, and pre-treatment procedures. Previous research has suggested that the ethanol and methanol extracts derived from MM leaves were non-toxic in concentrations up to 5000 mg/kg. Nevertheless, aqueous extracts should have a lower toxicity response when compared with other solvents. The question raised on MM, specifically in crude aqueous extracts obtained through different extraction techniques, might cause similar toxic responses. Therefore, this study was conducted to assess the acute and subacute toxicity of MM leaves' crude aqueous extract in Sprague Dawley rats for 14 and 28 days, respectively. The experiment will involve the observation of physical and behavioural changes. Analysis of blood and serum markers, along with a detailed examination of organ histopathology, will be conducted to thoroughly assess the level of MM toxicity effect. The outcomes of this study will offer valuable insights into the safety profile of MM crude aqueous extract.

MATERIALS AND METHODS

Preparation of Extract

Fresh MM leaves were collected from the headquarters of the Malaysian Agricultural Research and Development Institute (MARDI), Malaysia, located at longitude 101° 41' 26.2284", latitude: N 2° 59.8573'. The MM plant was deposited at Universiti Putra Malaysia (UPM) with voucher number SK3338/18. Freshly harvested leaves were washed and dried in a 50 °C dryer. The crude extract was prepared by adding 80 g of the plants' ground leaf material in 1600 ml boiling water and shaking at 200 rpm for 2 hours. The crude extract was then filtrated through No. 1001 (Whatman, Germany) filter paper. The solution was freeze-dried and kept in the freezer prior to use.

Experimental Animals

Healthy female Sprague Dawley rats with an approximate weight of 150-170 g were obtained from A Sapphire Enterprise (001303794-M), located at Seri Kembangan, Selangor, Malaysia. These rats were allowed to acclimatise for two weeks prior to this study. Standard commercial rat pellets (Gold Coin Mouse Pellet 702P, Malaysia) and water were provided *ad libitum* for the animals. Individual cages were provided for each rat within the same animal room. The housing environment was maintained under specific conditions: a temperature of 25 °C \pm 2 °C and a light-dark cycle of 12 hours each. These controlled conditions were upheld at the Animal Metabolism, Toxicity, and Reproductive Centre (AMTREC) within the Malaysian Agricultural and Research Development Institute (MARDI) located in Serdang, Selangor. The study was approved by the Malaysian Agricultural Research and Development, MARDI Animal Ethic Committee (AEC) under 20220422/R/MAEC00108. All procedures involving the care and treatment of the animals strictly adhered to the approval of the ethical guidelines.

Acute Oral Toxicity

Following the acclimatisation period, a total of ten female Sprague Dawley rats were randomly divided into two groups. One group was subjected to gavage with distilled water (vehicle) at a dosage of 5 ml/kg ($n = 5$). In contrast, the other group (as the treatment group) received a high dose of MM extract at a concentration of 3000 mg/kg ($n = 5$) administered using a force-feed needle. This oral force-feeding procedure was conducted once, and the MM extract was freshly prepared daily before each administration. The rats were monitored individually within 30 minutes, followed by periodic observations throughout the first 24 hours. Special attention was given to the first four hours of observation. The animals were subjected to daily monitoring over a total duration of 14 days. The study was conducted in accordance with the Organisation for Economic Co-operation and Development (OECD,

2001) guidelines for Acute Oral Toxicity—Fixed Dose Procedure with slight modifications as per system suitability.

Subacute Oral Toxicity

A total of 24 female Sprague Dawley rats were randomly allocated into four groups. The first group (Group 1) was the normal control, and the rats were administered distilled water (vehicle) at a dosage of 5 ml/kg ($n = 6$). The remaining rat groups were subjected to varying treatments, with each group receiving an equivalent volume of MM crude extract that had been dissolved in distilled water at concentrations of 100 mg/kg (Group 2), 500 mg/kg (Group 3), and 1000 mg/kg (Group 4) MM crude extract, respectively ($n = 6$). Throughout the study's 28 days, oral forced feed on rats was carried out daily. Throughout the 28-day experiment, the rats were subjected to daily observations. Rats were observed individually for the first 30 minutes after dosing and then periodically during the first 24 hours. Special attention was given during the first four hours. The study was conducted in accordance with the Organisation for Economic Co-operation and Development (OECD, 2008), and the Repeated Dose 28-Day Oral Toxicity procedure, with slight modifications as per system suitability.

Data Collection

Daily examinations were conducted to monitor any signs of toxicity in the rats, including changes in skin, fur, eyes, and mucous membranes, as well as somatomotor activity and behaviour. Any unusual or abnormal pattern was documented. Individual rat weights were recorded prior to the study's commencement and at intervals of seven days. The rats' food intake was calculated daily.

Haematological Analysis

At the end of the experiment, all rats were fasting for approximately 16 hours and were humanely euthanised using carbon dioxide inhalation. Once the rats were confirmed dead, a small blood sample was collected from the tail to assess blood glucose levels using an instant Glucometer (Accu-Chek Instant Blood Glucometer, India). Subsequently, the abdominal walls of the rats were carefully incised. Approximately 7–10 ml of whole blood was extracted from each rat through the vena cava. Bloods were preserved at ethylene diamine tetra acetic acid (EDTA)--containing vacutainer tubes (Becton, Dickinson and Company, UK) and were kept at 4°C. The blood samples were analysed using a fully automated Veterinary Haematology analyser (Exigo H400, Sweden). Parameters such as red blood cell count (RBC), haemoglobin (HGB), mean corpuscular haemoglobin (MCH), mean corpuscular haemoglobin concentration (MCHC), mean corpuscular volume (MCV), total white blood cell count (WBC), lymphocytes, monocytes, granulocytes, haematocrit

(HCT), platelets (PLT), mean platelet volume (MPV), and red cell distribution width (RDW) was obtained.

Serum Biochemistry Analysis

Freshly collected blood from the vena cava was kept in gel-activated plain clot tubes (non-EDTA-containing) vacutainers. These tubes were properly labelled and then centrifuged at 1500 g for 5 minutes to obtain the serum. The serum was placed in 1.5 ml tubes and stored at -20 °C. The serum tubes were sent to the Haematology & Clinical Biochemistry Laboratory within the Department of Veterinary Laboratory Diagnosis at the Faculty of Veterinary Medicine, UPM. The blood serum underwent the evaluation of parameters such as alkaline phosphatase (ALP), aspartate aminotransferase (AST), total protein (TP), albumin (Alb), globulin (Glo), total bilirubin (T. Bil), creatinine (Creat.), urea, and alanine aminotransferase (ALT).

Histopathology Study

The entire rat organs, including the kidney, liver, lungs, stomach, heart, and spleen, were harvested, and their organ weight was recorded. The kidney and liver were preserved in 10% buffered formalin and sent to the Veterinary Laboratory Service Unit (VLSU), Department of Veterinary Laboratory Diagnosis Faculty of Veterinary Medicine, UPM. Sections of these organs were subjected to staining using Haematoxylin and Eosin (H&E) and examined under a microscope at magnifications of 100×, 200×, and 400× to identify and analyse any potential pathological changes.

Statistical Analysis

All data were statistically analysed using Statistical Analysis Software (SAS) software SAS/STAT® 9.4 (Statistical Analysis Software, 2011). The values were presented as the mean ± standard error. Analysis of variance (ANOVA) was performed to assess variances between the data sets of different groups. Analysis of variance (ANOVA) was done to compare the differences in data between groups. A significance level of $p < 0.05$ was considered significant in statistical terms.

RESULTS AND DISCUSSION

Natural products from plants have been used extensively across the globe to address diverse ailments. However, the components derived from the plants need to undergo initial assessments to evaluate their toxicity profile for safety assurance. According to previous investigations (Alnajjar et al., 2012; Kamsani et al., 2019; Reduan et al., 2020; Zahi et al., 2017), MM extracts administered orally were considered safe in acute and sub-acute toxicity assessments.

Acute Toxicity

In the acute toxicity study, no mortality, morbidity, abnormal behaviour, or adverse clinical signs were observed at the tested dose of 3000 mg/kg throughout the 14-day study period. The postmortem examination showed no abnormal or gross pathology changes in any rats. Consequently, the estimated LD₅₀ of the extract in rats was expected to be higher than 3000 mg/kg.

Subacute Toxicity

Behaviour and Clinical Signs of Intoxication

Throughout the 28-day duration of the experiment, all groups were found healthy, and no treatment-related mortality and morbidity were attributed to the treatment (Table 1).

Table 1
Mortality and clinical signs of acute toxicity of Melastoma malabathricum (MM) crude extract administered orally to Sprague Dawley rats

Dose of MM extract (mg/kg)	Mortality	Abnormal behaviour/physical	Toxic symptoms
0	0/6	None	None
100	0/6	None	None
500	0/6	None	None
1000	0/6	None	None

Body Weight, Weight Gain and Feed Intake

Over the investigation period in the study, the mean body weight and weight gain of rats in the treated groups were similar to those of the normal control group, as summarised in Table 2. Nonetheless, on Day 14, Group II and Group III displayed slightly elevated values (189.25 + 2.75 g and 187.20 + 1.77 g, respectively) in comparison to the normal control group (172.00 + 4.71 g) (Figure 1). However, on Days 21 and 28, the body weight of the treated rats showed no significant difference ($p>0.05$) compared to the normal control group. Hence, the minor fluctuation observed in the mid-study can be considered within the realm of normal variability and does not suggest any substantial issues with the growth rates of the rats.

These findings were inconsistent with the regular feed intake (Figure 2). Potentially harmful extracts may undergo metabolism, yielding end-products that could adversely affect gastric function and impede food conversion efficiency (Ping et al., 2013). Such outcomes could lead to reduced food intake, indicating a loss of appetite, ultimately resulting in decreased body weight due to disruptions in carbohydrate, protein, or fat metabolism (Klaassen, 2018). In the study, none of the measured parameters in the treated

Table 2
The weekly body weight changes of rats during 28 days of subacute toxicity test with *Melastoma malabathricum* crude extract

Day of experiment	Mean body weight, g			
	Group I (0 mg/kg)	Group II (100 mg/kg)	Group III (500 mg/kg)	Group IV (1000 mg/kg)
0	158.25 ± 3.61 ^a _A	165.25 ± 7.59 ^a _A	167.00 ± 3.46 ^a _A	162.75 ± 2.88 ^a _A
7	166.00 ± 4.06 ^a _A	180.50 ± 5.23 ^a _B	175.50 ± 3.50 ^a _{AB}	167.80 ± 3.69 ^a _{AB}
14	172.00 ± 4.71 ^a _{AB}	189.25 ± 2.75 ^b _{BC}	187.20 ± 1.77 ^b _{BC}	180.67 ± 5.06 ^{ab} _B
21	184.79 ± 5.65 ^a _{BC}	196.68 ± 2.25 ^a _{CD}	192.77 ± 3.91 ^a _C	194.27 ± 4.27 ^a _C
28	191.27 ± 5.59 ^a _C	206.78 ± 4.15 ^a _D	195.26 ± 7.31 ^a _C	198.66 ± 4.13 ^a _C

Note. ^{a,b} Means in the same row with different superscripts are significantly different at $p<0.05$,
_{A,B,C,D} Means in the same column with different subscripts are significantly different at $p<0.05$

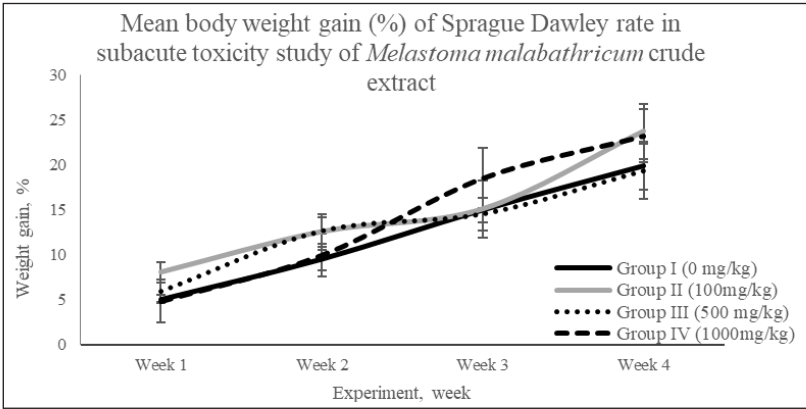


Figure 1. The weekly body weight gain changes of rats during subacute toxicity test with *Melastoma malabathricum* crude aqueous extract

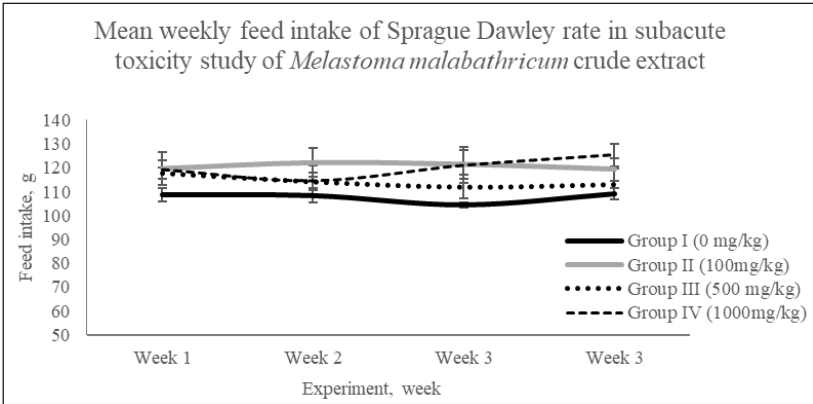


Figure 2. The weekly food intake changes of rats during subacute toxicity test with *Melastoma malabathricum* crude extract

groups exhibited noteworthy distinctions when compared to the normal control group. This indicates that MM extract did not influence carbohydrate, protein, or fat metabolism in the rats. Furthermore, the study revealed that the MM extract did not have a negative impact on weight gain, as seen in the control group when exposed to unrestricted food and water supply.

Haematology and Serum Biochemistry Analysis

The blood and serum obtained from the rats were subjected to haematological (Table 3) and serum biochemical (Table 4) analyses to validate the observations. The haematological parameter values can be measured to assess the adverse effects caused by compounds or extracts on the blood of tested animals. By evaluating haematological parameters, it is possible to determine the potential harm caused by the tested compounds or extracts on the blood (Kamsani et al., 2019).

Table 3
Haematological values of Sprague Dawley rats in Melastoma malabathricum’s crude extract-treated and control group

Parameters	Unit	Melastoma malabathricum’s crude extract (mg/kg)			
		Group I (0 mg/kg)	Group II (100 mg/kg)	Group III (500 mg/kg)	Group IV (1000 mg/kg)
Glucose	mmol/l	4.78 ± 0.14 ^a	5.45 ± 0.55 ^a	4.90 ± 0.16 ^a	4.70 ± 0.29 ^a
WBC	× 10 ⁹ /L	7.51 ± 0.67 ^a	9.93 ± 0.52 ^a	8.72 ± 0.65 ^a	7.98 ± 0.82 ^a
LYM	× 10 ⁹ /L	5.55 ± 0.53 ^a	7.33 ± 0.47 ^a	6.37 ± 0.52 ^a	5.96 ± 0.62 ^a
MONO	× 10 ⁹ /L	0.32 ± 0.06 ^a	0.33 ± 0.02 ^a	0.38 ± 0.10 ^a	0.40 ± 0.08 ^a
GRAN	× 10 ⁹ /L	1.65 ± 0.15 ^a	2.11 ± 0.25 ^a	1.96 ± 0.18 ^a	1.61 ± 0.18 ^a
LYM	%	73.95 ± 1.43 ^a	77.91 ± 2.52 ^a	72.85 ± 2.27 ^a	74.73 ± 1.88 ^a
MON	%	3.13 ± 0.52 ^a	2.60 ± 0.14 ^a	4.11 ± 0.77 ^a	4.16 ± 0.82 ^a
GRA	%	22.92 ± 1.45 ^a	19.48 ± 2.45 ^a	23.03 ± 1.94 ^a	22.76 ± 2.78 ^a
HGB	g/dl	17.98 ± 0.40 ^a	16.57 ± 0.55 ^a	16.85 ± 0.75 ^a	17.93 ± 0.29 ^a
HCT	%	48.46 ± 1.09 ^a	44.98 ± 1.58 ^a	46.05 ± 1.93 ^a	48.40 ± 0.64 ^a
RBC	× 10 ¹² /L	9.46 ± 0.20 ^a	8.84 ± 0.28 ^a	8.94 ± 0.41 ^a	9.53 ± 0.11 ^a
MCV	fl	51.18 ± 0.37 ^a	51.91 ± 0.42 ^a	51.67 ± 0.60 ^a	51.86 ± 0.93 ^a
MCH	pg	19.00 ± 0.09 ^a	19.13 ± 0.22 ^a	18.85 ± 0.21 ^a	18.70 ± 0.37 ^a
MCHC	g/dl	37.12 ± 0.14 ^a	36.85 ± 0.24 ^a	36.51 ± 0.19 ^a	36.63 ± 0.23 ^a
RDW	%	19.16 ± 0.27 ^a	19.05 ± 0.33 ^a	19.80 ± 0.47 ^a	19.35 ± 0.18 ^a
RDWa	fl	36.90 ± 0.19 ^a	37.17 ± 0.61 ^a	38.10 ± 0.77 ^a	38.23 ± 0.91 ^a
PLT	× 10 ⁹ /L	951.50 ± 47.28 ^a	945.17 ± 91.74 ^a	947.67 ± 55.41 ^a	947.50 ± 39.71 ^a
MPV	fl	4.62 ± 0.09 ^a	4.96 ± 0.08 ^b	5.05 ± 0.08 ^b	4.85 ± 0.11 ^{ab}

Note. ^{a,b} Means in the same row with different superscripts are different significantly at *p*<0.05

Table 4

Serum biochemistry values of Sprague Dawley rats in Melastoma malabathricum's crude extract-treated and control group

Parameters	Unit	<i>Melastoma malabathricum's</i> crude extract (mg/kg)			
		Group I (0mg/kg)	Group II (100 mg/kg)	Group III (500 mg/kg)	Group IV (1000 mg/kg)
ALP	U/L	164.05 ± 12.08 ^a	205.74 ± 21.64 ^a	232.09 ± 62.43 ^a	202.08 ± 31.71 ^a
AST	U/L	138.91 ± 5.92 ^a	149.35 ± 7.51 ^a	170.07 ± 21.39 ^a	150.83 ± 8.11 ^a
TP	g/L	68.06 ± 0.79 ^a	65.73 ± 1.54 ^a	66.96 ± 2.75 ^a	70.13 ± 5.23 ^a
ALB	g/L	41.33 ± 0.85 ^a	40.52 ± 3.29 ^a	37.58 ± 4.15 ^a	43.85 ± 0.64 ^a
Glo	g/L	26.75 ± 1.30 ^a	25.22 ± 3.28 ^a	29.38 ± 3.62 ^a	26.90 ± 5.98 ^a
A:G	Unit	1.57 ± 0.11 ^a	1.81 ± 0.30 ^a	1.50 ± 0.35 ^a	1.80 ± 0.43 ^a
TBil	umol/L	2.73 ± 0.34 ^a	2.72 ± 0.38 ^a	2.88 ± 0.77 ^a	1.92 ± 0.20 ^a
Creat	umol/L	59.00 ± 2.46 ^a	59.00 ± 1.61 ^a	57.17 ± 3.46 ^a	51.25 ± 2.35 ^a
Urea	mmol/L	7.80 ± 0.27 ^a	8.23 ± 0.25 ^a	7.95 ± 0.47 ^a	7.90 ± 0.49 ^a
ALT	U/L	51.00 ± 1.89 ^a	51.83 ± 2.98 ^a	51.93 ± 4.84 ^a	45.00 ± 4.39 ^a

Note. ^{a,b} Means in the same row with different superscripts are different significantly at $p < 0.05$

The haematological parameters of the rats administered with various concentrations did not differ significantly ($p > 0.05$) compared to the control group. However, a deviation was observed in the mean platelet volume (MPV) between the control group and groups II and III. These groups exhibited higher MPV values (4.96 ± 0.08 fl and 5.05 ± 0.08 fl, respectively) when compared to the normal control group (4.62 ± 0.09 fl) (Table 3). Nevertheless, Group IV (4.85 ± 0.11 fl) demonstrated no significant deviations when compared to any other groups ($p > 0.05$). Despite the statistically significant disparities, the distinctions in MPV values between Group II, Group III, and the remaining groups were relatively small. These variances were minor and unlikely to lead to any irregularities in the rats under investigation. Petterino and Argetino-Storino (2006) reported a narrower range of normal MPV values for Sprague Dawley rats (3.60–4.40 fl) when compared to the measurements obtained in our study. Conversely, earlier investigations by He et al. (2017) and Lillie et al. (1996), focusing on the same rat species, presented considerably broader normal MPV ranges (6.60–8.30 fl and 5.38–5.90 fl, respectively). These variations could be attributed to differences in experimental settings, diets, or environmental factors. Furthermore, the highest concentration group (1000 mg/kg) exhibited no significant distinctions compared to the normal control group. Considering the slight variations observed in Group II and Group III, it is not conclusive that the tested herbs were toxic to the subjects. Overall, based on the sub-acute toxicity test, it can be reasonably concluded that MM can be deemed safe for oral administration in Sprague Dawley rats.

The liver and kidney are the vital organs that play a crucial role in determining an organism's overall well-being and survival (Zhang et al., 2016). Whether acute or

chronic, liver damage is often associated with elevated serum levels of AST (aspartate aminotransferase) and ALT (alanine aminotransferase). ALT, predominantly found in the liver, serves as a widely recognised biomarker for hepatotoxicity, and it is a specific indicator of liver dysfunction that potentially signals hepatocellular necrosis. In contrast, while AST can aid in identifying hepatocellular necrosis, it is regarded as a less specific biomarker for liver injury due to the possibility of its serum levels rising in response to dysfunction in other organs as well. Consequently, the assessment of ALT and AST levels, alongside total bilirubin (TBil), is a standard recommendation for evaluating hepatocellular injury in rodents during nonclinical investigations (Fishman, 1990; Kamsani et al., 2019; Sriuttha et al., 2018).

The urea, creatinine, and uric acid levels are among the parameters used to assess renal dysfunction. This also means if these indicators fall within the established normal range, it implies the absence of renal complications (Barnett and Cumming, 2018). The urea, creatinine, and uric acid levels within the groups treated with MM crude aqueous extract exhibited no difference compared to the control group. This suggests that the renal function remained unaffected in the treated groups during the toxicity analysis (Table 4). The results of the experiment provided sufficient evidence to conclude that oral administration of MM crude aqueous extract was safe and presented no toxicity effect even when consumed at high doses of 3,000 mg/kg and 100, 500 and 1000 mg/kg using acute and sub-acute toxicity tests, respectively.

Histopathology Study

The liver and kidney exhibited no adverse effects or clinical signs of toxicity during the histopathology analysis (Table 5). However, considering the importance of histopathology in completing the toxicology test, major organs, such as the liver and kidney, were selected. These organs are the focus of histopathology examinations due to their crucial functions in detoxifying and eliminating harmful substances from the body's metabolic processes. Consequently, these organs are susceptible to the impact of toxic compounds (Elufioye et al., 2009).

Relative organ weight percentage showed no significant difference in the kidney, liver, lung, heart, spleen, and stomach (Table 5). In subacute toxicity studies, microscopic assessments of kidneys and livers from both control and treated groups revealed normal histopathology features (Figure 3). The kidneys displayed typical histopathology characteristics, including glomeruli, tubules, interstitium, and blood vessels. Meanwhile, liver sections from the control and treatment rats exhibited intact hepatocellular structures, clearly visible central veins, and an absence of any anomalies. Importantly, the treatments for the rats did not yield any adverse impacts on the histopathology arrangement of hepatocytes.

Table 5

Effect of Melastoma malabathricum crude extract on relative organ weight percentage of Sprague Dawley rats in subacute toxicity study

Parameters	<i>Melastoma malabathricum</i> 's crude extract (mg/kg)			
	Group I (0 mg/kg)	Group II (100 mg/kg)	Group III (500 mg/kg)	Group IV (1000 mg/kg)
Kidney	0.71 ± 0.02 ^a	0.07 ± 0.03 ^a	0.73 ± 0.03 ^a	0.73 ± 0.03 ^a
Liver	2.94 ± 0.10 ^a	2.88 ± 0.08 ^a	3.16 ± 0.11 ^a	3.14 ± 0.07 ^a
Lung	0.60 ± 0.02 ^a	0.58 ± 0.03 ^a	1.08 ± 0.45 ^a	0.64 ± 0.03 ^a
Heart	0.36 ± 0.01 ^a	0.34 ± 0.01 ^a	0.36 ± 0.02 ^a	0.34 ± 0.02 ^a
Spleen	0.17 ± 0.01 ^a	0.34 ± 0.01 ^a	0.23 ± 0.06 ^a	0.21 ± 0.01 ^a
Stomach	0.61 ± 0.01 ^a	0.60 ± 0.04 ^a	0.63 ± 0.02 ^a	0.62 ± 0.01 ^a

Note. ^{a,b} Means in the same row with different superscripts are different significantly at $p < 0.05$

Under microscopic observations, the histopathology slides under H&E staining did not yield significant deviant changes from toxicity effects attributed to the extract's oral administration (Figure 3). Treatment of MM crude aqueous extract did not yield any alterations in organ colour or appearance or signs of hypertrophy. No modifications in cell architecture or pathological abnormalities were detected under the light microscope. As Mirza and Pancha (2019) pointed out, relative organ weights in toxicity studies indicate particular organs in detecting significant toxicity-related changes in vital organs such as the kidneys, liver, heart, stomach, spleen, and lungs.

The MM crude aqueous extracts demonstrated good tolerance among the experimental animals under investigation. Throughout the study period, acute and sub-acute toxicity tests observed no mortality or significant changes in physical appearance, behaviour, food consumption, or body weight that deviated from the normal control group. Furthermore, assessments encompassing blood haematological analysis, serum biochemistry, and histopathological examination indicated the absence of any indications of toxic effects in rats subjected to acute and sub-acute toxicity tests.

Female Sprague Dawley rats were selected as the experimental subjects for this study because the intended population for the test substance was females. Utilising female rats exclusively can yield more pertinent data for risk assessment within the target population (Zahi et al., 2017). Furthermore, conducting toxicity studies can be resource-intensive and costly. Opting for a more streamlined approach that utilises fewer animals and causes reduced distress while maintaining the ability to rank the substance's toxicity comparably makes focusing solely on female rats.

Additionally, female rats generally exhibit greater sensitivity to toxic substances compared to males in toxicity studies (OECD, 2001; Zahi et al., 2017). Earlier preliminary screenings involving acute and sub-acute toxicity tests of similar extracts, utilising male

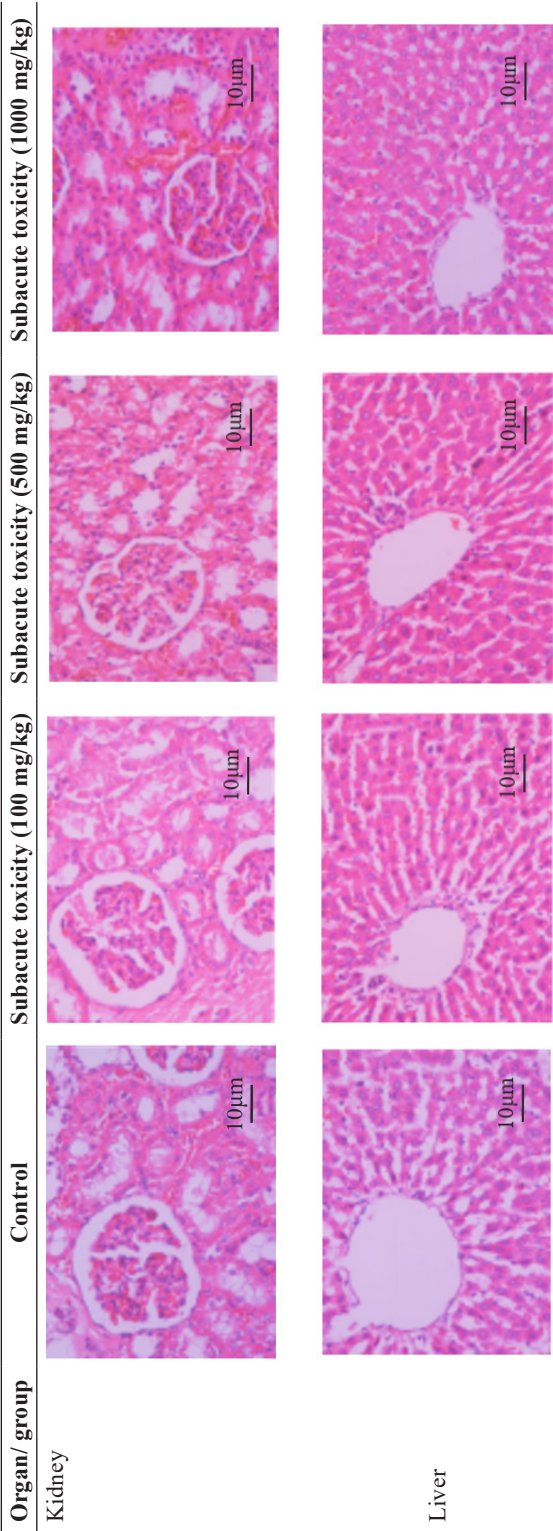


Figure 3. Histopathology assessment of the rat's organs (liver and kidney) for control and treated rats group with 3000 mg/kg (acute toxicity test) and 100, 500 and 1000 mg/kg (subacute toxicity test) of *Melastoma malabathricum* crude aqueous extract

and female rats, did not reveal significant discrepancies in toxicity based on sex (Alnajjar et al., 2012; Kamsani et al., 2019; Manicam et al., 2013; Zahi et al., 2017). Based on a rational foundation and the existing evidence, the decision to exclusively use female rats for the study is a pragmatic choice to enhance cost-effectiveness, minimise redundant efforts, and allocate resources optimally while still producing valuable toxicity insights.

CONCLUSION

The oral administration of MM crude aqueous extract for 14 days in the acute study and 28 days in the subacute study did not cause any detrimental effects on behaviour, body weight, haematological and biochemical indicators, relative organ weight, or histopathology analysis. Consequently, no Observed Adverse Effect Level (NOAEL) was established at doses greater than 3000 mg/kg and 1000 mg/kg for the acute and subacute toxicity studies, respectively.

CONFLICT OF INTEREST

The authors declare no conflict of interest.

ACKNOWLEDGEMENTS

Special thanks to Dr. Rosly Mohd Shaari's research team at the Livestock Science Research Centre, Malaysian Agricultural Research and Development (MARDI) for their invaluable facilities and expert advice throughout this research.

REFERENCES

- Alnajjar, Z. A. A., Abdulla, M. A., Ali, H. M., Alshawsh, M. A., & Hadi, A. H. A. (2012). Acute toxicity evaluation, antibacterial, antioxidant and immunomodulatory effects of *Melastoma malabathricum*. *Molecules*, 17(3), 3547-3559. <https://doi.org/10.3390/molecules17033547>
- Barnett, L. M. A., & Cummings, B. S. (2018). Nephrotoxicity and renal pathophysiology: A contemporary perspective. *Toxicological Sciences*, 164(2), 379-390. <https://doi.org/10.1093/toxsci/kfy159>
- Choudhury, M. D., Nath, D., & Talukdar, A. D. (2011). Antimicrobial activity of *Melastoma malabathricum* L. *Biological and Environmental Sciences*, 7(1), 76-78.
- Elufioye, T. O., Alatise, F. A., & Fakoya, J. M. (2009). Toxicity studies of *Tithonia diversifolia* A. Gray (Asteraceae) in rats. *Journal of Ethnopharmacology*, 122(2), 410-415. <https://doi.org/10.1016/j.jep.2008.12.007>
- Fishman, W. H. (1990). Alkaline phosphatase isozymes: Recent progress. *Clinical Biochemistry*, 23(2), 99-104. [https://doi.org/10.1016/0009-9120\(90\)80019-F](https://doi.org/10.1016/0009-9120(90)80019-F)
- He, Q., Su, G., Liu, K., Zhang, F., Jiang, Y., Gao, J., Liu, L., Jiang, Z., Jin, M., & Xie, H. (2017). Sex-specific reference intervals of hematologic and biochemical analytes in Sprague-Dawley rats using the

- nonparametric rank percentile method. *PLoS ONE*, 12(12), e0189837. <https://doi.org/10.1371/journal.pone.0189837>
- Kamsani, N. E., Zakaria, Z. A., Nasir, N. L. M., Mohtarrudin, N. & Alitheen, N. B. M. (2019). Safety assessment of methanol extract of *Melastoma malabathricum* L. leaves following the subacute and subchronic oral consumptions in rats and its cytotoxic effect against the HT29 cancer cell line. *Hindawi Evidence-Based Complementary and Alternative Medicine*, 2019(1), 5207958. <https://doi.org/10.1155/2019/5207958>
- Klaassen, C. D. (2018). *Casarett and Doull's Toxicology: The basic science of poisons*. McGraw-Hill Education. <https://accesspharmacy.mhmedical.com/book.aspx?bookid=2462>
- Kumar, V., Ahmed, D. M., Gupta, D. A., Anwar, F., & Mujeeb, M. (2013). Anti-diabetic, anti-oxidant and anti-hyperlipidemic activities of *Melastoma malabathricum* Linn. leaves in streptozotocin induced diabetic rats. *Complementary and Alternative Medicine*, 13, 222. <https://doi.org/10.1186/1472-6882-13-222>
- Lillie, L. E., Temple, N. J., & Florence Z. (1996). Reference values for young normal Sprague-Dawley rats: Weight gain, hematology and clinical chemistry. *Human & Experimental Toxicology*, 15(8), 612-616. <https://doi.org/10.1177/096032719601500802>
- Manicam, C., Khoo, L. T., Abdullah, J. O., Tohit, E. R. M., Seman, Z., Siew, C. C., & Hamid, M. (2013). Subacute toxic effects of *Melastoma malabathricum* Linn. aqueous leaf extract on liver and kidney histopathology of rats. *International Journal of Pharmacology*, 9(6), 358-365. <https://doi.org/10.3923/ijp.2013.358.365>
- Mazura, M. P., Susanti, D., & Rasadah, M. A. (2007). Anti-inflammatory action of components from *Melastoma malabathricum*. *Pharmaceutical Biology*, 45(5), 372–375. <https://doi.org/10.1080/13880200701214797>
- Mirza, A. C., & Pancha, S. S. (2019). Safety evaluation of syringic acid: Subacute oral toxicity studies in Wistar rats. *Heliyon*, 5(8), e02129. <https://doi.org/10.1016/j.heliyon.2019.e02129>
- Organisation for Economic Co-operation and Development. (2001). *Test No. 423: Acute oral toxicity – Acute toxic class method (OECD guidelines for the testing of chemicals, section 4)*. OECD Publishing. <https://doi.org/10.1787/9789264071001-en>
- Organisation for Economic Co-operation and Development. (2008). *Test No. 407: Repeated dose 28-day oral toxicity study in rodents (OECD guidelines for the testing of chemicals, section 4)*. OECD Publishing. <https://doi.org/10.1787/9789264070684-en>
- Petterino, C., & Argentino-Storino, A. (2006). Clinical chemistry and haematology historical data in control Sprague-Dawley rats from pre-clinical toxicity studies. *Experimental and Toxicologic Pathology*, 57(3), 213-219. <https://doi.org/10.1016/j.etp.2005.10.002>
- Ping, K. Y., Darah, I., & Chen Y. Sreeramanan S., & Sasidharan S. (2013). Acute and subchronic toxicity study of *Euphorbia hirta* L. methanol extract in rats. *BioMed Research International*, 2013, 182064. <https://doi.org/10.1155/2013/182064>
- Reduan, F. H., Shaari, R. M., Sayuti, N. S. A., Mustapha, N. M., Bakar, M. Z, A. B., Sithambaram, S., & Hamzah, H. (2020). Acute and subacute dermal toxicity of ethanolic extract of *Melastoma malabathricum* leaves in Sprague-Dawley rats. *Toxicology Research*, 36, 203-210. <https://doi.org/10.1007/s43188-019-00013-5>

- Sriuttha, P., Sirichanchuen, B., & Permsuwan, U. (2018). Hepatotoxicity of nonsteroidal anti-inflammatory drugs: A systematic review of randomized controlled trials. *International Journal of Hepatology*, 2018(1), 5253623. <https://doi.org/10.1155/2018/5253623>
- Zahi, A. K., Hamzah, H., Shaari, M. R., Widodo, R. T., Johnny, L., Noordin, M. M., & Sithambaram, S. (2017). Investigation and evaluation of acute and sub-acute dermal toxicity studies of ethanolic leaves extract of *Melastoma malabathricum* in Sprague Dawley rats. *International Journal of Current Research in Medical Science*, 3(5), 84-99. <http://doi.org/10.22192/ijcrms.2017.03.05.013>
- Zhang, Y., Guan, E., Zhao, X., Wang, B., Yin, L., Zhang, L., Huang, J., & Fu, X. (2016). A subchronic toxicity study of ethanol root extract of baked *Aconitum flavum* in rats. *Revista Brasileira de Farmacognosia*, 26(4), 438-445. <https://doi.org/10.1016/j.bjp.2016.03.004>